



# Aegean Journal of Obstetrics and Gynecology

## Case Report

### Uterus-sparing myomectomy for idiopathic uterine pyomyoma in a young woman: A case report

Uğur Şen<sup>a, †</sup>, Tuğba Karadeniz<sup>b</sup>, Emrah Beyan<sup>a</sup>

<sup>a</sup> Department of Obstetrics and Gynecology, University of Health Sciences Tepecik Education and Research Hospital, İzmir, TURKEY

<sup>b</sup> Department of Pathology, University of Health Sciences Tepecik Education and Research Hospital, İzmir, TURKEY.

#### ABSTRACT

**Objective:** Pyomyoma or suppurative leiomyoma is a rare but serious complication of uterine fibroids. Leiomyoma is an infection that occurs on the ground of necrosis due to ischemia. Pregnancy, intrauterine interventions, postmenopausal status and uterine artery embolization are the most common risk factors. Although rare, it can be seen in the absence of any risk factors.

**Case Report:** The patient, who was 36 years old and had no known risk factors for pyomyoma admitted with abdominal pain and fever, was describing an increase in the amount of menstrual bleeding for 1 year. In the examinations, a 12 cm leiomyoma was detected. During the operation, the myoma was ruptured and yellow grey bad-odour pus was seen. The patient was diagnosed with pyomyoma. Since she had a desire for fertility, uterus-sparing myomectomy was performed, and treatment was continued with broad-spectrum antibiotics. On the 10th postoperative day, the patient was discharged with healing.

**Conclusion:** Forty-eight pyomyoma cases have been reported in MEDLINE Database. The case we present is the 5th idiopathic uterine pyomyoma. Keeping this rare gynecological entity in mind and treating it with appropriate surgery and antibiotherapy will prevent mortality, morbidity and loss of fertility.

**Keywords:** pyomyoma; leiomyoma; uterine myomectomy; fertility sparing

#### ARTICLE INFO

Doi: 10.46328/aejog.v2i2.43

#### Article history:

Received: 15 July 2020

Revision received 22 July 2020

Accepted 09 August 2020

© 2020 AEJOG.

## Introduction

Pyomyoma, or suppurative leiomyoma, is a rare but serious complication of uterine fibroids [1]. Cases usually occur in the premenopausal period. As it can be seen during the course of pregnancy, it may occur after abortion or birth [2]. It can also develop after uterine instrumentation or due to cervical stenosis [3]. Pyomyoma cases have also been reported after uterine artery embolization, which has recently gained popularity as an alternative to surgical treatment of myomas [4].

The mechanism of pyomyoma is infection caused by microorganisms coming from ascending or hematogenously on the ground of necrosis following ischemia and infarction [5]. Since pyomyoma is rare and can take a long time to develop, its diagnosis is difficult. Patients often present with pain and fever. It should be considered in cases had no other etiology of fever and had a history of uterine fibroids [1,4]. The patients may have signs of peritonitis caused by ruptured pyomyoma [6]. There are no specific findings in MRI and CT or other imaging techniques [2,3]. Diagnosis and treatment are often delayed due to non-specific presentation and imaging findings. This delay increases the risk of mortality and morbidity such as fertility loss [7]. The case we presented is a premenopausal and sexually inactive woman without any history of pregnancy or uterine instrumentation or immunocompromised.

The case we presented is a premenopausal and sexually inactive woman without any history of pregnancy or uterine instrumentation or immunocompromised. She desired to preserve her fertility. This patient is the 5th case of idiopathic uterine pyomyoma and the 3rd case that was successfully treated with myomectomy. Knowing the proper treatment of pyomyoma will be beneficial to prevent potential mortality and morbidity.

## Case Report

The patient, 36 years old, applied with a complaint of increasing pelvic pain for a week. There was only one birth in her obstetric story, which was performed 8 years ago by cesarean (G1P1). She stated that she had a fever for 2 days, although it was not measured. She said that her menstrual cycles are regular, but the amount of menstrual bleeding has increased in the last 1 year and she has not applied for gynecological examination. She had no known additional diseases. In her evaluation, it was determined that there was tenderness in the lower pelvic region, and the uterus was mobile, painful and large about the age of 12 weeks gestation. The cervix had a nulliparous appearance and no abnormal discharge was observed. Bilateral ovaries and fallopian tubes were observed normally, and a 12 cm solid uterine mass originated from corpus anterior was detected with magnetic resonance imaging (MRI).

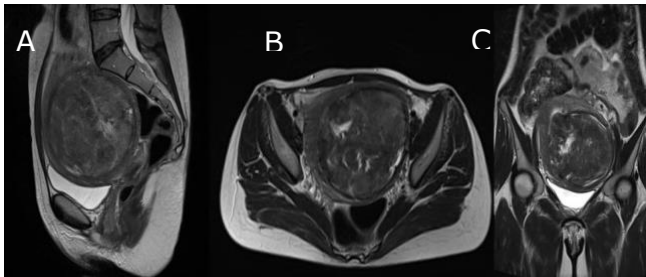
<sup>†</sup> Corresponding author.

E-mail: dr.ugursen@gmail.com

Orcid Id: 0000-0001-6131-137X

The mass was pressing the endometrium and containing cystic areas compatible degeneration (Figure 1).

Figure 1. MRI scan prior to the operation



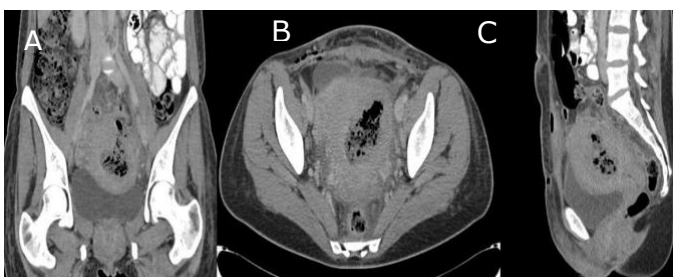A; T2-weighted sagittal section, B; T2-weighted horizontal section, C; T2-weighted coronal section

With these findings, the mass was thought as degenerative leiomyoma. In the complete blood count, hemoglobin (Hb): 10.1 grams/dL and white blood cell count (WBC): 14.000 cells/mcL were detected. C-reactive protein (CRP) value was 15 mg/L and CA-125 value was 76 U/mL. Apart from this, routine preoperative examinations were usual. An abdominal myomectomy was planned for the patient due to uterine leiomyoma.

Before the operation, 1 gr of intravenous cefazolin was administered, and it was entered into the abdomen under regional anesthesia in a supine position with a pfannenstiell incision. 10 cm vertical incision made from the anterior of the uterus. The fibroid could not be easily dissected from the surrounding myometrium. The 12 cm fibroid was ruptured while trying to extrude. Smelly yellow grey colored pus was emptied from inside. The fibroid center is grey and fragmented. A culture antibiogram was taken from cavitation containing pus and at the border of the myometrium, which seemed clean. Without entering the endometrial cavity, fibroid was enucleated. Myometrium and uterine serosa were closed three layers with absorbable sutures. The abdomen was washed with 2000 mL saline. A 0.8 mm diameter silicone drain was placed in the Douglas and the abdominal layers were closed in accordance with the anatomy.

In the postoperative 1st day, intravenous 1 gr ceftriaxone 2 times a day and 500 mg metronidazole 3 times a day were started as empirical antibiotherapy. For thromboembolism prophylaxis, 4000 IU of enoxaparin sodium was started. The patient had an uneventful postoperative first day and had 100 mL of serohemorrhagic drainage and vital signs were normal. In laboratory examination, WBC: 20 cells/mcL Hb: 7.6 grams/dL CRP: 16 mg/L procalcitonin: 1.7 ng/mL were detected. The patient was mobilized, and oral food intake was started. In the evening of the 2nd postoperative day, the patient's body temperature reached 39 degrees Celsius. Urine and blood cultures were taken. Fever control was achieved with intravenous paracetamol. When whole abdominal computerized tomography (CT) scan was performed.

Figure 2. CT scan on the second postoperative day

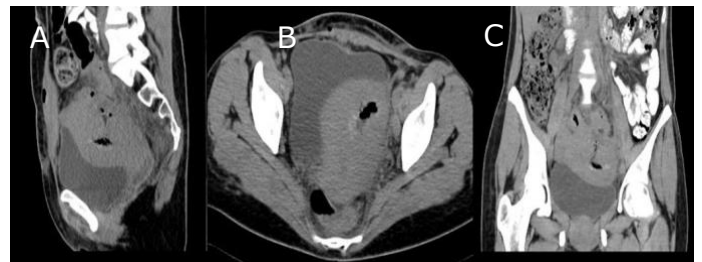

Hypodense area with air formation compatible with the abscess appears in the fibroid localization within the uterus. A. Coronal section B. Horizontal section C. Sagittal section

In the location of the fibroid, 6 cms hypodense area included irregular air formation was detected consistent with abscess (Figure 2).

In the postoperative 3rd day, since aerobic and anaerobic blood cultures were positive, meropenem parenteral was started 1g 3 times a day. Other antibiotherapies were stopped. In laboratory examination, WBC: 23 cells/mcL Hb: 7.3 grams/dL CRP: 19 mg/L procalcitonin: 1.9 ng/mL were detected. Two units of erythrocyte suspension were transfused. In the following days, despite fever reached 39 degrees Celsius, since the patient's clinic was improved the meropenem treatment was continued. Between the postoperative 7th and 10th day, fever was not detected. In the CT scan, the diameter of the abscess decreased to 3 cm (Figure 3).

Figure 3. CT scan on the 10th postoperative day



The abscess formation appears to be limited and decreased. A. Sagittal section B. Horizontal section C. Coronal section

After the clinical findings completely returned to normal, the abdominal drain was removed, parenteral meropenem treatment was stopped and oral metronidazole 500 mg 3 times a day and cefixime 400 mg 2 times a day was prescribed, and the patient was discharged.

One week after discharge, it was observed that the patient's complaints completely disappeared and in the ultrasonographic evaluation, the pelvic genital organs returned to their normal anatomy. During this time, the pathology result was confirmed. In the pathological examination, it was reported that polymorph nuclear cells surrounding the necrotic myometrium fibers were observed and the specimen was compatible with pyomyoma.

## Discussion

Pyomyoma is a rare but serious complication of uterine fibroids and is mostly seen in the pregnancy-related and postmenopausal status or after uterine instrumentation [8]. Our case is a rare exception, as the patient had no risk factor in terms of development of pyomyoma. The patient did not have a history of fibroids since she had not applied for a gynecological examination for a long time. It is possible that she had rapid growth of the fibroid leading to ischemic changes and degeneration.

Cases usually occur in the premenopausal period. As it can be seen during the course of pregnancy, it may occur after abortion or birth. It can also develop after uterine instrumentation or due to cervical stenosis [9]. Only 3 cases that developed during the course of pregnancy were reported. The cause of postmenopausal cases may be related to both vascular and immune deficiency caused by diseases such as diabetes, atherosclerosis and hypertension. Infections are generally polymicrobial [13]. In addition, the infection can occur with hematogenous or lymphatic spread [14]. In cases developing in the early postpartum period or after uterine instrumentation, ascending infection is thought to be responsible [7]. Especially in postpartum hemorrhage, intrauterine balloon application causes both infarction due to bleeding and development of infection [15]. After 1996, with

the increase of uterine artery embolization as an alternative to surgical treatment of myomas, the number of associated pyomyoma cases increased [4]. Eight cases related to UAE have been reported and the frequency of reporting has increased especially after 2010 [4]. This is thought to be a result of ischemia.

Since 1986, 48 pyomyoma cases have been reported in MEDLINE Database. 23 of these cases were associated with pregnancy, while only 3 cases were seen during pregnancy. Among the cases not related to pregnancy, the most common reason was UAE. While 6 cases were associated with postmenopausal conditions, there is any etiological cause for 4 cases as in our case. Our case is the fifth case with no etiological cause. Apart from these, rare causes such as IUD, PID, bacterial sepsis, diabetes and torsion of the pedunculated fibroid have also been reported. The mean age and min-max range of all cases and their subgroups are summarized in Table 1.

Table 1. Etiology of cases

Etiology, N (%)		Age (Mean ± sd)	Age (min-max)
Pregnancy related	Total, 23 (47.9 %)	33.3 ± 4.8	26-44
	After Pregnancy, 20 (41.7 %)	33.1 ± 4.3	26-41
	During Pregnancy, 3 (6.2 %)	34.3 ± 8.5	28-44
Non- pregnancy	Total, 25 (52.1 %)	48.3 ± 12.5	24-75
	UAE*, 8 (16.7 %)	44.3 ± 11	28-65
	Postmenopausal, 6 (12.5 %)	64.0 ± 8.9	49-75
	Unknown, 4 (8.3 %)	39.8 ± 10.7	24-47
	Others, 7 (14.6 %)	44.4 ± 4.7	38-53
Total, 48 (100%)		41.3 ± 12.2	24-75

\*UAE: uterine artery embolization

Since pyomyoma is rare and can take a long time to develop, its diagnosis is difficult. Patients often present with pain and fever. It should be considered in cases had no other etiology of fever and had a history of uterine fibroids. Postmenopausal patients may have symptoms of malignancy such as abdominal distention and bloating, anorexia, and changes in defecation [17]. There may be a serious elevation in Ca 125 level [21], but usually, a moderate elevation occurs, as in our case. Imaging techniques are generally not diagnostic. The definitive diagnosis is usually made by surgery. Ultrasound shows a heterogeneous uterine mass containing areas of cystic degeneration [20,22]. Abulafia et al. argued that an anechoic halo of normal myometrium surrounding the mass can be diagnostic ultrasound [22]. CT shows findings similar to ultrasound, but its diagnostic value is higher than USG, as it shows more prominent intra-abdominal and intra-mass air formation [3,20]. MRI does not show any specific findings like USG and has no diagnostic value [2]. The differential diagnoses are also conditions that require surgical treatment and includes pyometra, tuba ovarian abscess, an infected ectopic pregnancy, malignancy, intestinal perforation, or degenerating fibroids [15,23]. The most serious complication of pyomyoma is rupture. Afterwards, sepsis and even death can be seen [4,14]. In the presence of clinical signs such as deterioration in the patient's vital values, imaging techniques may show irregularity in the mass wall, free fluid and air in the abdomen.

The appropriate treatment is mostly delayed because the symptoms of pyomyoma patients are non-specific and there is no definitive diagnostic imaging technique [21]. Treatment of pyomyoma is almost always surgical [9]. It is managed with hysterectomy or myomectomy according to the fertility request and the severity of the patient's condition. Occasionally, conservative treatment with drainage, accompanied by antibiotics, can be an alternative treatment. In the case series presented by Laubach et al, they reported that antibiotic therapy and drainage with interventional radiology was successful in 2 of 3 cases, but in 1 of 3 cases hysterectomy was required [24]. There are 3 more cases in the literature that have been successfully managed with drainage. There is only one case, presented by Stroumsa et al, treated with parenteral antibiotics without major surgery or drainage [25]. Greenspoon et al reported that the patient treated with antibiotics alone died [14]. Hysterectomy was performed in 24 (50%) of 48 cases in the literature, and myomectomy was performed in 17 (35.4%). The mean age of hysterectomy cases was 47, while the mean age of myomectomy cases was 34. Twelve (70%) of myomectomy cases were associated with pregnancy. It seemed that patient age and fertility request are determinants of hysterectomy or myomectomy decision. We also decided to treat with myomectomy since our patient was 36 years old and has fertility request (Table 2).

Table 2. Treatment of cases

Treatment, N (%)	Age (Mean ± sd)	Age (min-max)
Hysterectomy, 24 (50 %)	46.8 ± 12	31-75
Myomectomy, 17 (35.4 %)	34.3 ± 10.7	24-67
Drainage and antibiotics, 5 (10.4 %)	35.4 ± 4.2	31-42
Only antibiotics, 2 (4.2%)	45 ± 5.7	41-49

The mean age and standard deviation of 4 cases with unknown etiological causes are 39.8 ± 10.7 and the min-max interval (24-47). Zengeneh et al were treated with hysterectomy because the patient was 47 years old and there was no fertility request [19]. Liu H et al, on the other hand, made a diagnosis in the diagnostic laparotomy in a 42-year-old case who developed sepsis due to ruptured pyomyoma and marsupialized and drained the ruptured myoma [20]. They preferred minimally invasive treatment to the patient whose vital signs were critical. Read et al, at the age of 24 and is the youngest case in the literature performed a successful myomectomy [9]. Chen et al. also treated the 46-year-old pyomoyoma case with a successful myomectomy [8]. Considering the literature, our case is 18th case treated with myomectomy, 5th case of unknown cause and 3rd case in which pyomyoma developed in the absence of predisposing factor was successfully treated with myomectomy (Table 3).

Table 3. The cases without risk factor

Author, Year	Age	Treatment
Zengeneh, 2010 [26]	47	Hysterectomy
Chen ZH, 2010 [8]	46	Myomectomy
Liu, 2011 [27]	42	Drainage and antibiotics
Read, 2018. [9]	24	Myomectomy
Present case, 2020	36	Myomectomy

Pyomyoma is a rare gynecological emergency that can occur in cases of vascular or immunodeficiency, where uterine instrumentation is performed mostly in pregnancy and postmenopausal women. It is often a polymicrobial infection that develops on the background of fibroid ischemia. It is a local infection initially, but when ruptured it can cause peritonitis and sepsis. It is an entity that has a mortality risk and may cause fertility loss when treatment is delayed. It can develop in the absence of predisposing factor, as in the case we present.

In the presence of uterine fibroids, fever and pelvic pain, a rare gynecological urgent mind should also be considered when there is no reason to explain these symptoms. Empirical broad-spectrum antibiotics should be started as soon as possible, and surgical intervention should be performed.

## Disclosure

Authors have no potential conflicts of interest to disclose.

## References

[1] Bagga R, Rai R, Kalra J, Saha PK, Singh T. An unusual cause of postabortal fever requiring prompt surgical intervention: A pyomyoma and its imaging features. *Oman Med J*. 2017 Jan 1;32(1):73–6.

[2] Ono H, Kanematsu M, Kato H, Toyoki H, Hayasaki Y, Furui T, et al. MR imaging findings of uterine pyomyoma: Radiologic-pathologic correlation. *Abdom Imaging*. 2014;39(4):797–801.

[3] Karcaaltincaba M, Sudakoff GS. CT of a Ruptured Pyomyoma. *Am J Roentgenol*. 2003;181(5):1375–7.

[4] Obele CC, Dunham S, Bennett G, Pagan J, Sung LY, Charles HW. A Case of Pyomyoma following Uterine Fibroid Embolization and a Review of the Literature. *Case Rep Obstet Gynecol*. 2016;2016.

[5] Yeat SK, Chong KM, Pan HS, Cheng WC, Hwang JL, Lee CC. Impending sepsis due to a ruptured pyomyoma with purulent peritonitis: A case report and literature review. *Taiwan J Obstet Gynecol*. 2005 Mar 1;44(1):75–9.

[6] Del Borgo C, Maneschi F, Belvisi V, Morelli F, Vetica A, Marocco R, et al. Postpartum fever in the presence of a fibroid: *Sphingomonas paucimobilis* sepsis associated with pyomyoma. *BMC Infect Dis*. 2013 Dec 5;13(1).

[7] Pinton A, Aubry G, Thoma V, Nisand I, Akladios CY. Pyomyoma after abortion: Uterus conserving surgery is possible to maintain fertility. *Case report*. *Int J Surg Case Rep*. 2016 Jan 1;24:179–81.

[8] Chen ZHY, Tsai H Der, Sun MJ. Pyomyoma: A Rare and Life-threatening Complication of Uterine Leiomyoma. *Taiwan J Obstet Gynecol*. 2010;49(3):351–6.

[9] Read S, Mullins J. Spontaneous Ruptured Pyomyoma in a Nulligravid Female: A Case Report and Review of the Literature. *Case Rep Obstet Gynecol*. 2018;2018.

[10] Prahlow JA, Cappellari JO, Washburn SA. Uterine pyomyoma as a complication of pregnancy in an intravenous drug user. *South Med J*. 1996;89(9):892–5.

[11] Grüne B, Zikulnig E, Gembruch U. Sepsis in second trimester of pregnancy due to an infected myoma: A case report and a review of the literature. *Fetal Diagn Ther*. 2001;16(4):245–7.

[12] Kobayashi F, Kondoh E, Hamanishi J, Kawamura Y, Tatsumi K, Konishi I. Pyomayoma during pregnancy: A case report and review of the literature. *J Obstet Gynaecol Res*. 2013 Jan;39(1):383–9.

[13] Sah SP, Rayamajhi AK, Bhadani PP. Pyomyoma in a postmenopausal woman: a case report. *Southeast Asian J Trop Med Public Health*. 2005 Jul;36(4):979–81.

[14] Greenspoon JS, Ault M, James BA, Kaplan L. Pyomyoma Associated with Polymicrobial Bacteremia and Fatal Septic Shock: Case Report and Review of the Literature. *Obstet*

*Gynecol Surv*. 1990 Sep 1;45(9):563–9.

[15] Kaler M, Gailer R, Iskaros J, David AL. Postpartum Pyomyoma, a Rare Complication of Sepsis Associated with Chorioamnionitis and Massive Postpartum Haemorrhage Treated with an Intrauterine Balloon. *Case Rep Obs Gynecol*. 2015;2015(2015):609205.

[16] Chen JR, Yang TL, Lan FH, Lin TW. Pyomyoma mimicking advanced ovarian cancer: A rare manifestation in a postmenopausal virgin. *Taiwan J Obstet Gynecol*. 2014;53(1):101–3.

[17] Genta PR, Dias ML, Janiszewski TA, Carvalho JP, Arai MH, Meireles LP. *Streptococcus agalactiae* endocarditis and giant pyomyoma simulating ovarian cancer. *South Med J*. 2001 May;94(5):508–11.

[18] Gupta A, Gupta MM, Manaktala U. Ascending infection causing pyomyoma in a young woman. *Egypt J Radiol Nucl Med*. 2014 Sep 1;45(3):1017–20.

[19] Zangeneh M, Alsadat Mahdavi A, Amini E, Davar Siadat S, Karimian L. Pyomyoma in a premenopausal woman with fever of unknown origin. *Obstet Gynecol*. 2010 Aug;116(2 PART 2):526–8.

[20] Liu HS, Chen CH. Subserosal pyomyoma in a virgin female: Sonographic and computed tomographic imaging features. *Ultrasound Obstet Gynecol*. 2011;37(2):247–8.

[21] Iwahashi N, Mabuchi Y, Shiro M, Yagi S, Minami S, Ino K. Large uterine pyomyoma in a perimenopausal female: A case report and review of 50 reported cases in the literature. *Mol Clin Oncol*. 2016;5(5):527.

[22] Abulafia O, Shah T, Salame G, Miller MJ, Serur E, Zinn HL, et al. Sonographic features associated with post-uterine artery embolization pyomyoma. *J Ultrasound Med*. 2010 May 1;29(5):839–42.

[23] DeMaio A, Doyle M. Pyomyoma as a Rare Source of Postpartum Sepsis. *Case Rep Obs Gynecol*. 2015;2015(2015):263518.

[24] Laubach M, Breugelmanns M, Leyder M, Demey J, Foulon W. Nonsurgical treatment of pyomyoma in the postpartum period. *Surg Infect (Larchmt)*. 2011 Feb 1;12(1):65–8.

[25] Stroumsa D, Ben-David E, Hiller N, Hochner-Celnikier D. Severe Clostridial Pyomyoma following an Abortion Does Not Always Require Surgical Intervention. *Case Rep Obs Gynecol*. 2011;2011(2011):364641.